

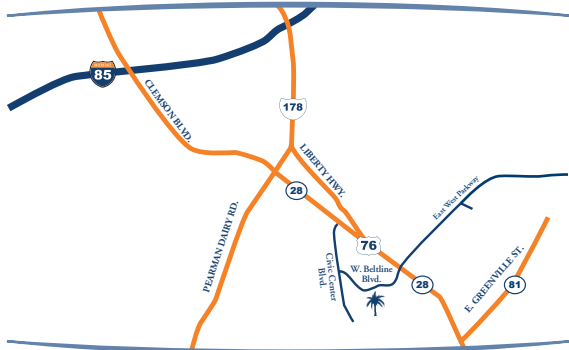


# Southern Endodontics

ROOT CANAL SPECIALIST

Rodney G. Southern, DMD, MS

[www.southernendosc.com](http://www.southernendosc.com)



**Directions:** From I-85 take exit 19A to Anderson on Clemson Blvd. Drive approximately 3 miles on Clemson Blvd., and Turn Right onto Beltline Blvd., by Tuckers Restaurant. Go 0.3 miles and Turn Left onto Broadbent Way. The office is located at 109 Broadbent Way in the Beltline Professional Park



# Southern Endodontics

ROOT CANAL SPECIALIST

**Rodney G. Southern, DMD, MS**

[www.southernendosc.com](http://www.southernendosc.com)

Introducing \_\_\_\_\_

Referred by Dr. \_\_\_\_\_

Phone \_\_\_\_\_ Date \_\_\_\_\_

	Molars			Bicuspid		Anteriors						Bicuspid		Molars			
Right	1	2	3	4	5	6	7	8	9	10	11	12	13	14	15	16	Left
	32	31	30	29	28	27	26	25	24	23	22	21	20	19	18	17	

- Symptoms Indicate Root Canal Treatment Needed
- History Of Pulp Exposu
- Previous Root Canal Therapy
- X-Ray Revealed Radiolucency
- Patient Has Vague Toothache. Please Evaluate
- Restoration With Post Planned. Post Space Desired
- Other

Comments \_\_\_\_\_

\_\_\_\_\_

\_\_\_\_\_

Appointment Date \_\_\_\_\_ Time \_\_\_\_\_